

PROFILE DESIGNER

iphysio[®]



“SIMPLICITY IS THE ULTIMATE SOPHISTICATION”

Leonardo da Vinci

Distributed by

LYRA[™]

ARE ESTHETICS
AND THE RESPECT
OF BIOLOGICAL
FACTORS
COMPATIBLE WITH
SIMPLICITY
AND RAPIDITY

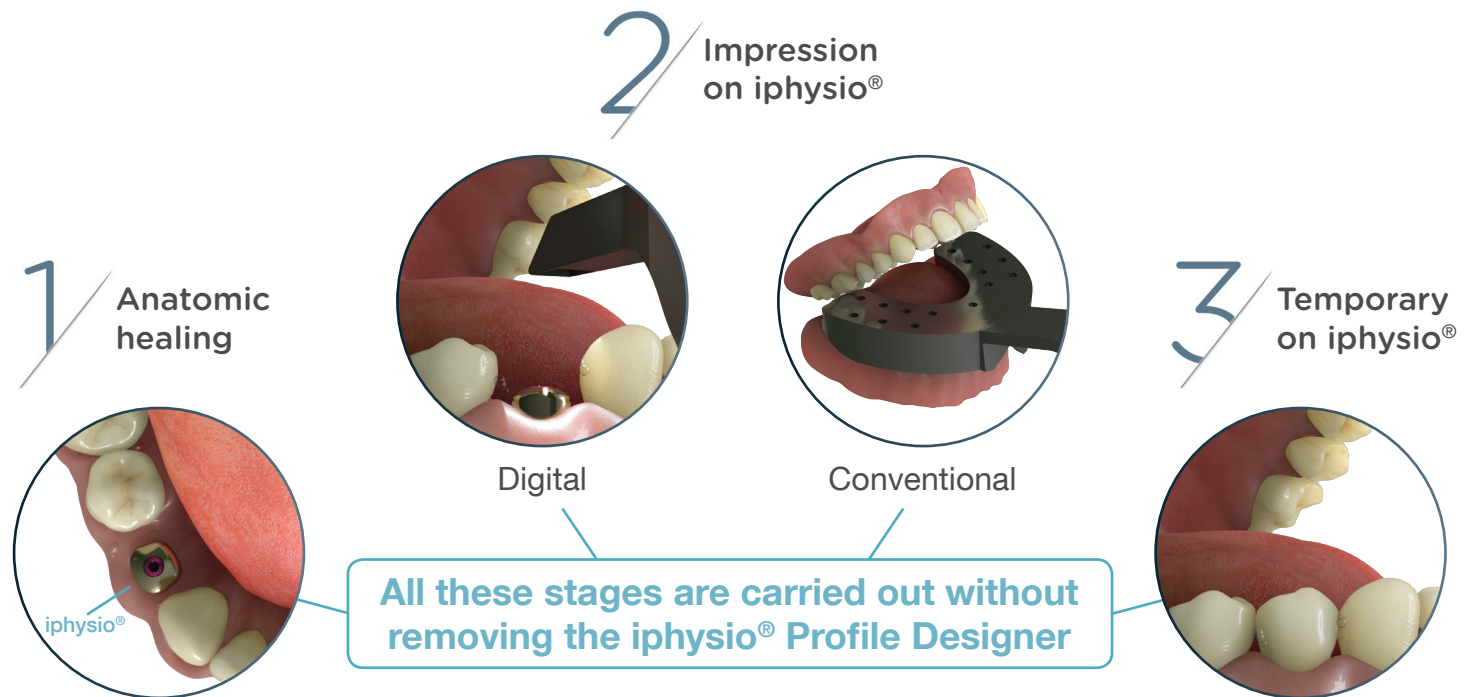
?

“ SIMPLICITY IS THE ULTIMATE SOPHISTICATION ”

Leonardo da Vinci

PRESERVATION OF THE BIOLOGICAL SPACE

The iphysio® Profile Designer is screwed into the implant during the 1st or the 2nd surgical intervention. It remains in place throughout the bone and gingival healing process as well as during the taking of an impression irrespective of the implant sector, whether aesthetic or not. It is only removed once to place and finally screw in the final restoration.



A 3 IN 1 SOLUTION

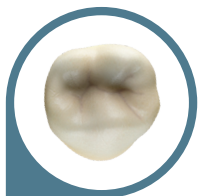
The Profile Designer fulfils 3 essential functions of the prosthetic protocol:

- 1. Healing:** its anatomic form fully meets with the morphology of the teeth to be replaced.
- 2. Taking of impressions:** using digital or conventional technology, the taking of the impression directly on the Profile Designer avoids positioning errors linked to the placement of the impression coping. The implant position is restored in a very accurate manner.
- 3. The temporary prosthesis:** resting on the Profile Designer, it takes the same shape as the prosthetic cradle up until the placement of the final prosthesis.


« iphysio®, the perfect complement to the CAD CAM anatomical abutment! The gingiva is sculpted from the healing stage, then the chosen emergence profile is preserved during the impression. Time saving, reduction in number of sessions. »

Dr Gian Marco Morello (Italy)

WHY IS THE IPHYSIO® PROFILE DESIGNER NOT ROUND ?

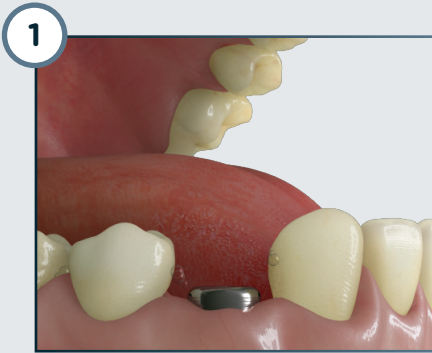


Teeth
are not
round

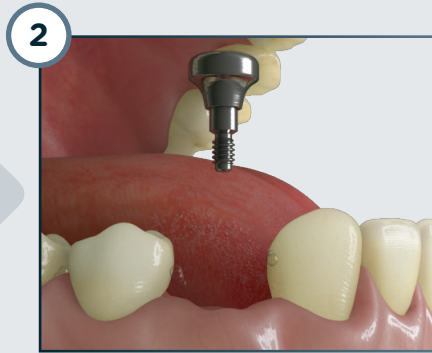


Nor are our
Profile
Designers

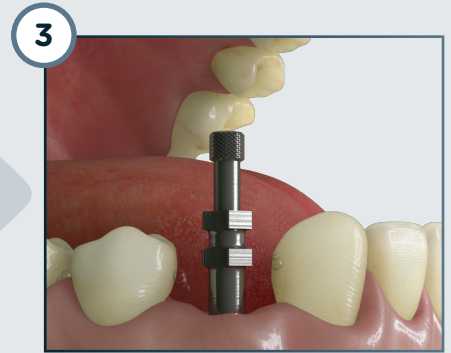
TRADITIONAL PROTOCOL



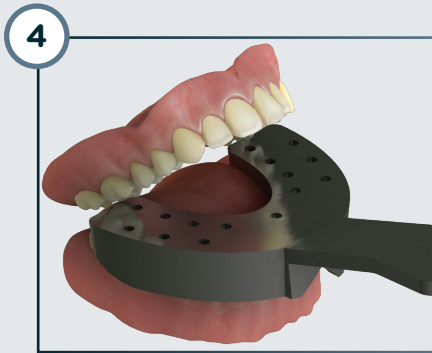
Screwing of the healing abutment



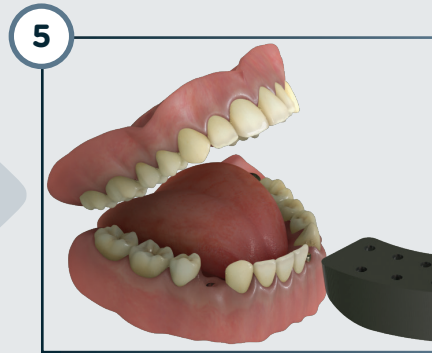Removal of the healing abutment



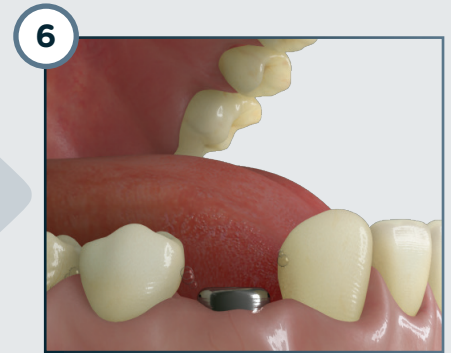
Screwing of the impression coping



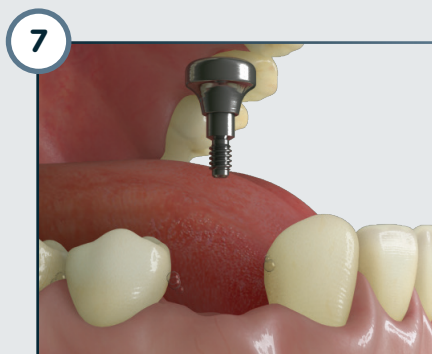
Taking of impression



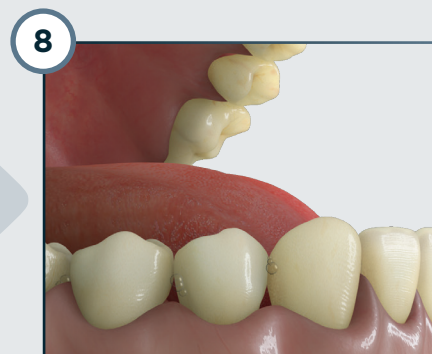
Removal of the impression tray



Screwing of the healing abutment

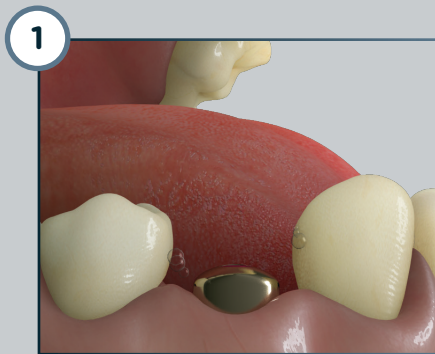

Removal of the healing abutment

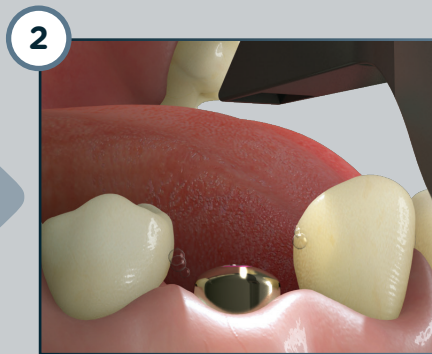


Placement of the final prosthesis

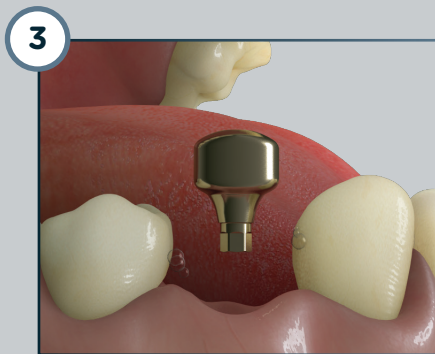
IPHYSIO® PROTOCOL



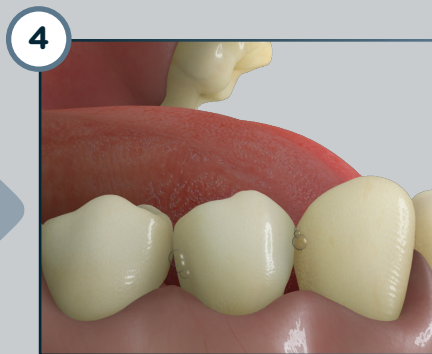
Screwing of the iphysio® Profile Designer



Taking of the digital or conventional impression



Removal of the iphysio® Profile Designer



Placement of the final prosthesis

4
STEPS IN
THE MOUTH
INSTEAD OF
8


SIMPLICITY
RAPIDITY

3
SUB-GINGIVAL
INTERVENTIONS
INSTEAD OF
8

RESPECT OF
BIOLOGICAL
FACTORS

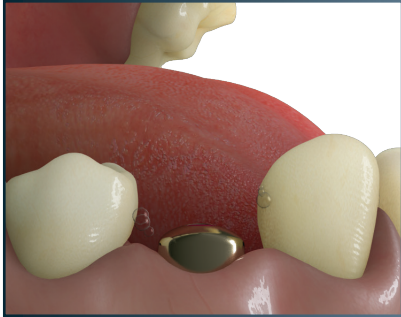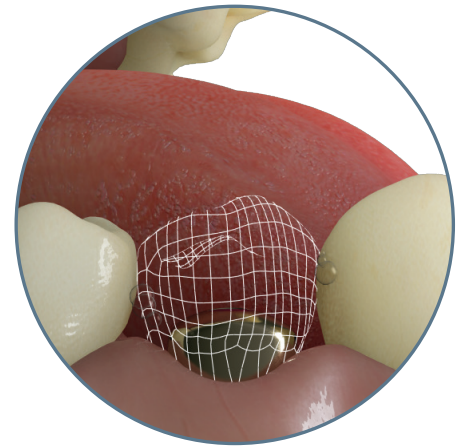
SIMPLIFICATION OF THE POST-SURGICAL PROTOCOL

The solution is based on the study of the anatomy and simultaneous use of the digital chain, thus allowing for the establishment of a much more compact and rapid protocol, which respects the patient physiology: the iphysio® protocol.

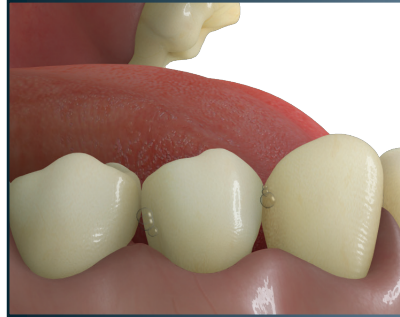

COMPLETION OF A TEMPORARY TOOTH

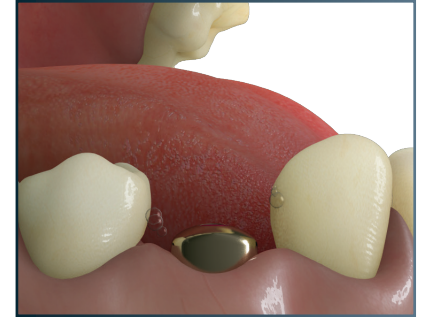The design of the iphysio® Profile Designer makes it possible to create on iphysio® a supra-gingival temporary tooth without modifying the part for the taking of impressions in the future.



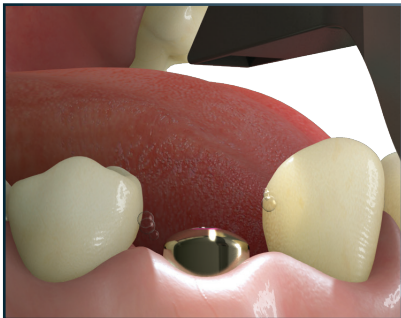
Screwing of the iphysio® Profile Designer



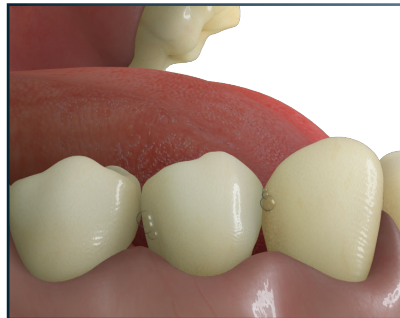Placement of the temporary tooth on iphysio®



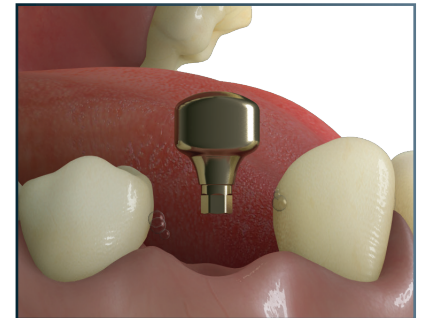
Removal of the temporary tooth



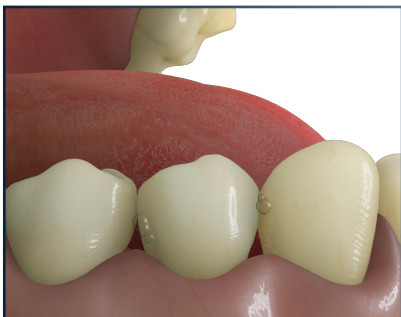Digital impression



Replacement of the temporary tooth on iphysio®



Removal of the temporary tooth and the Profile Designer



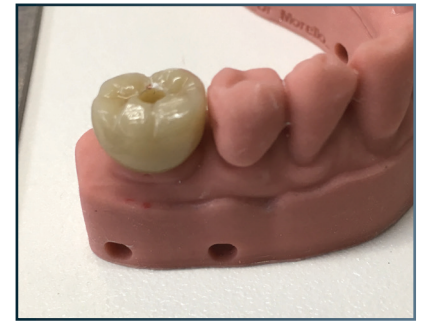
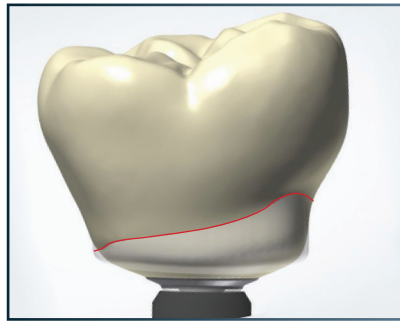
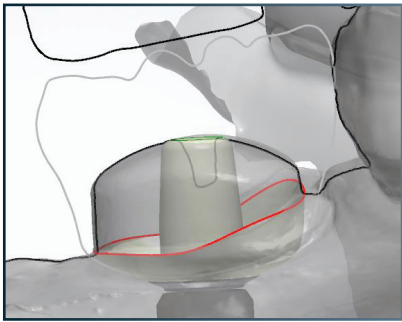
Placement of the final prosthesis

« Temporary prosthesis on iphysio® are simple to perform, they are screw-free, non-surgical, tissue-friendly, shape the gingiva with a physiological emergence profile and optimize aesthetic management. »

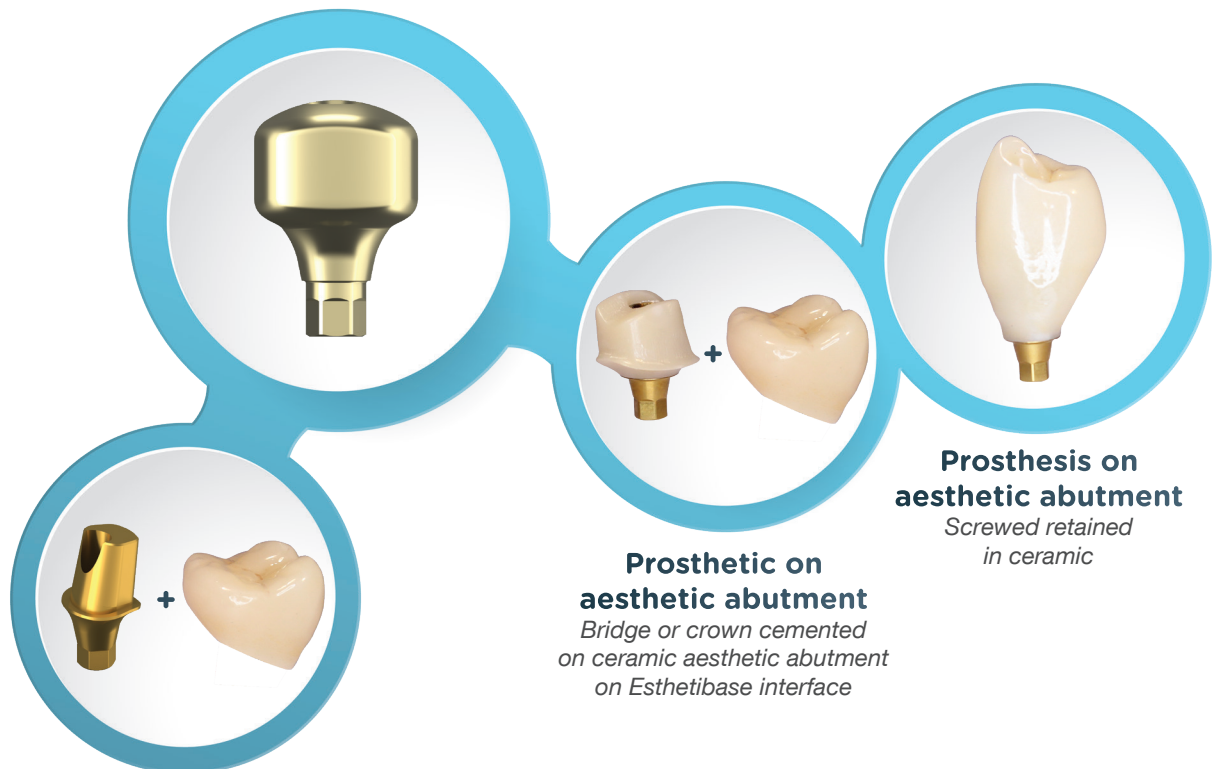
Dr François Asselborn (France - 74)

COMPLETION OF THE FINAL PROSTHESIS WITH RECOVERY OF THE EMERGENCE PROFILE

The iphysio® concept facilitates the automatic recovery of the sub-gingival emergence profile by the dental technician for the creation of the customised solutions both with the cemented prosthesis and the screwed retained prosthesis.



FINAL ANATOMICAL AND AESTHETIC PROSTHETIC ALTERNATIVES

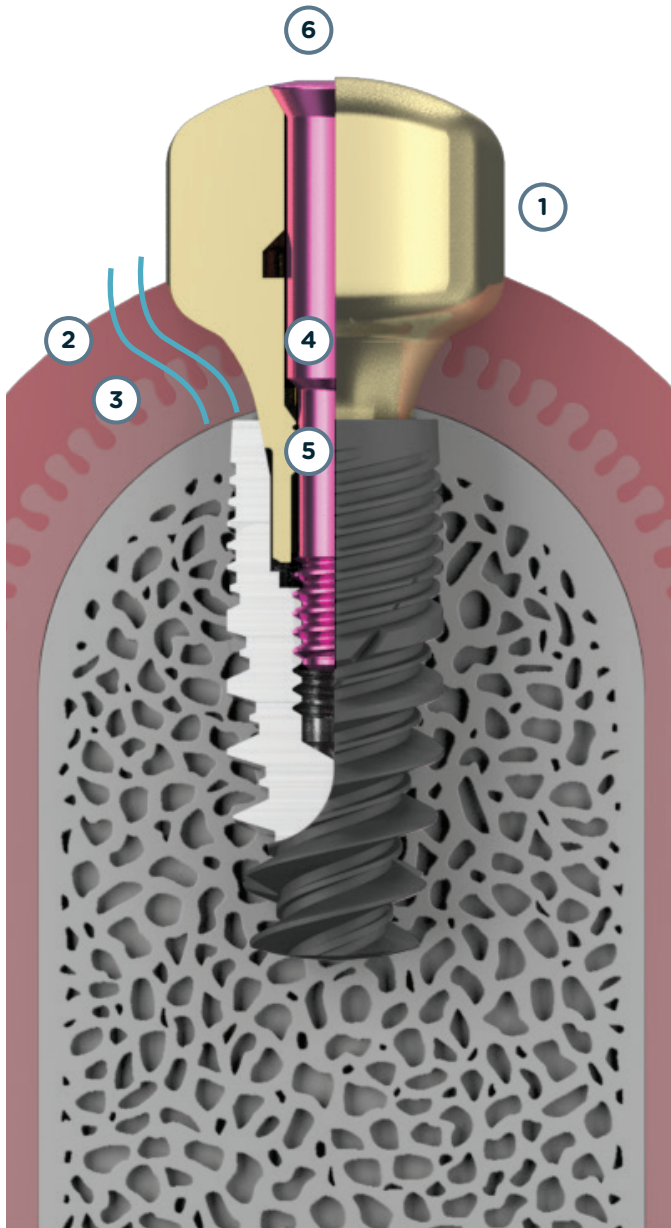



Prosthesis on anatomical abutment
Bridge or crown cemented on titanium anatomical abutment

Prosthesis on aesthetic abutment
Bridge or crown cemented on ceramic aesthetic abutment on Esthetibase interface

Prosthesis on aesthetic abutment
Screwed retained in ceramic

A CONCENTRATION OF KNOWLEDGE AND EXPERIENCE



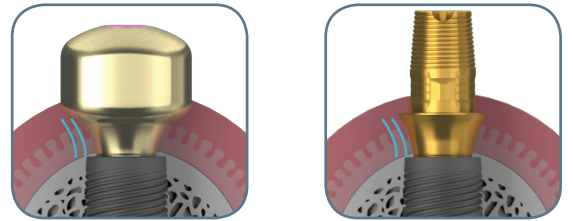
1 « Zirconia » coated titanium

- Limits the attachment of bacterial plaque: reduction of inflammation of the peri-iphysio[®] tissue
- Scanning precision: no deformations
- Improved scannability with intra-oral scanners


2 Continuity of the emergence profile of the implant up to the concave/convex coronal surface

- Gum preservation
- Better gingival stability
- Better osseointegration
- Avoids peri-implantitis
- Limits peri-implant bone resorption

3 Emergence profile perfectly suited to the Esthetibase titanium interfaces supporting the restorations sealed or screwed retained in zirconia



4 Coloured screw for identification of the Profile Designer height



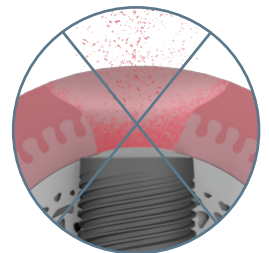
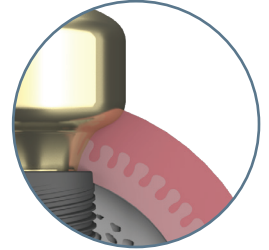
5 « Captive » screw for transporting the abutment without risk of falling out

6 Conical seal on the screw head, for advanced bacterial control

« *A major (R)evolution which, over and above providing comfort and respect for biological factors, will help you save valuable time. »*

RESPECT FOR BIOLOGICAL FACTORS

- Reduction of number of soft tissue interventions
 - Preservation of the mucosa attachment and the biological width
 - Reduction in peri-implantitis risks
- Papilla guiding
- No risk of contamination of the implant site during removal of the parts for the taking of the impression and the insertion of the temporary prosthesis

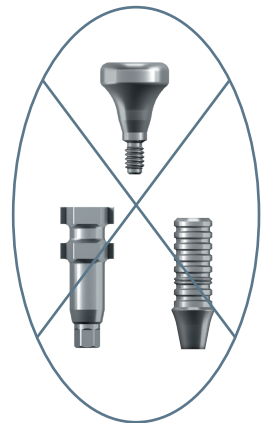


SIMPLIFICATION AND RATIONALISATION OF THE PROTOCOL

- Only 1 part required to do it all: healing, impression and temporary
- Homothety of the profiles between the iphysio® Profil Designers and the Esthetibase titanium interfaces

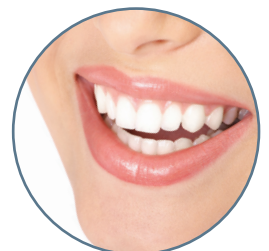PROGRESS IN THE DENTAL PRACTICE

- Time saving
- Fewer components to manage (in the case of a digital impression)
- Ideal for referrals owing to simplification of the parts management
 - No purchase of impression copings and analogs
 - Less handling
 - A simplified protocol



IMPROVEMENT IN THE PATIENT EXPERIENCE

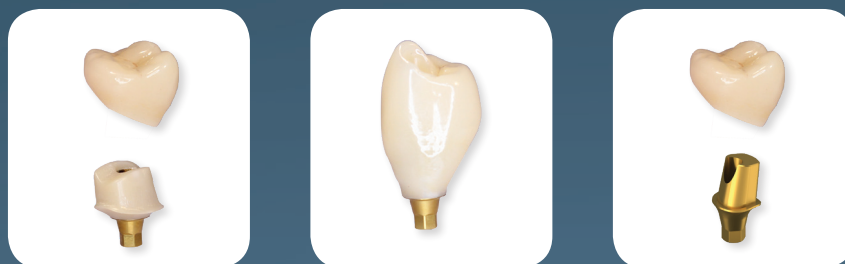- Comfort in taking the impression (no pain owing to the change of component)
- Time saving
- Reduction in the number of sessions
- Aesthetic result



BIBLIOGRAPHICAL REFERENCES

- **The mucosal barrier following abutment dis/reconnection. An experimental study in dogs.**
Abrahamsson I, Berglundh T, Lindhe J. Department of Periodontology, Göteborg University, Sweden.
J Clin Periodontol. 1997 Aug;24(8):568-72.
- **Nonremoval of immediate abutments in cases involving subcrestally placed postextractive tapered single implants: a randomized controlled clinical study.**
Degidi M1, Nardi D, Daprile G, Piattelli A.
Clin Implant Dent Relat Res. 2014 Dec;16(6):794-805. doi: 10.1111/cid.12051. Epub 2013 Mar 4.
- **Evaluation of antibacterial activity and osteoblast-like cell viability of TiN, ZrN and (Ti1-xZrx)N coating on titanium.**
Ji MK, Park SW, Lee K, Kang IC, Yun KD, Kim HS, Lim HP
J Adv Prosthodont. 2015 Apr;7(2):166-71. doi: 0.4047/jap.2015.7.2.166. Epub 2015 Apr 23.
- **Microbial community composition on modified dental implant surfaces: an in vivo study.**
Rehman A, Hu J, Ott SJ, Grössner-Schreiber B.
Int J Oral Maxillofac Implants. 2012 Jul-Aug;27(4):811-9.
- **Modified implant surfaces show different biofilm compositions under in vivo conditions.**
Grössner-Schreiber B, Teichmann J, Hannig M, Dörfer C, Wenderoth DF, Ott SJ.
Clin Oral Implants Res. 2009 Aug;20(8):817-26. doi: 10.1111/j.1600-0501.2009.01729.x. Epub 2009 Jun 7.
- **Plaque formation on surface modified dental implants. An in vitro study.**
Grössner-Schreiber B, Griepentrog M, Hausteil I, Müller WD, Lange KP, Briedigkeit H, Göbel UB.
Clin Oral Implants Res. 2001 Dec;12(6):543-51.
- **Peri-implant soft tissue conditioning with provisional restorations in the esthetic zone: the dynamic compression technique.**
Wittneben JG., Belser UC, Buser D. e Coll.
Int J Periodontics Restorative Dent. 2013 Jul-Aug;33(4):447-55. doi: 10.11607/prd.1268.
- **The effect of mucosal cuff shrinkage around dental implants during healing abutment replacement**
Nissan J, Zenziper E, Rosner O, Kolerman R, Chaushu L, Chaushu G.
J Oral Rehabil. 2015 Oct;42(10):774-8. doi: 10.1111/joor.12315. Epub 2015 Jul 1.

YOUR IMPLANT PROSTHESIS WITH OUR LYRA PARTNER LABORATORIES



LYRA™

25 rue Bleue 75009 Paris - FRANCE
07531 182273
info@lyra.dental
www.iphysio.dental

WWW.IPHYSIO.DENTAL